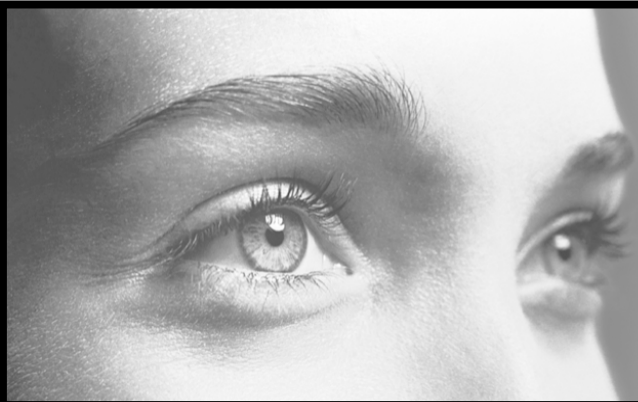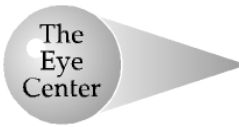




Ophthalmology • Refractive Surgery
Laser, Cataract & Implant Surgery

The Cornea and Corneal Disease

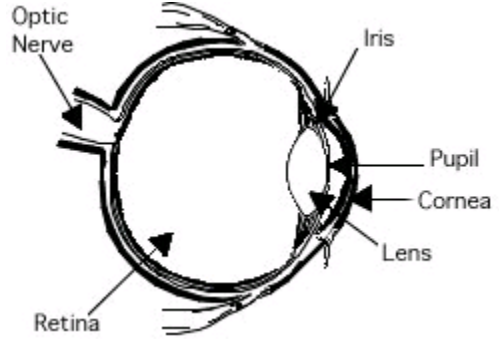
www.theeyecenter.com



Ophthalmology • Refractive Surgery
Laser, Cataract & Implant Surgery

The Cornea and Corneal Disease

What is the cornea?



The cornea is the eye's outermost layer. It is the clear, dome-shaped surface that covers the front of the eye.

Structure of the Cornea

Although the cornea is clear and seems to lack substance, it is actually a highly organized group of cells and proteins. Unlike most tissues in the body, the cornea contains no blood vessels to nourish or protect it against infection. Instead, the cornea receives its nourishment from the tears and aqueous humor that fills the chamber behind it. The cornea must remain transparent to refract light properly, and the presence of even the tiniest blood vessels can interfere with this process. To see well, all layers of the cornea must be free of any cloudy or opaque areas.

The corneal tissue is arranged in five basic layers, each having an important function. These five layers are:

Epithelium

The epithelium is the cornea's outermost region, comprising about 10 percent of the tissue's thickness. The epithelium functions primarily to: (1) Block the passage of foreign material, such as dust, water, and bacteria, into the eye and other layers of the cornea; and (2) Provide a smooth surface that absorbs oxygen and cell nutrients from tears, then distributes these nutrients to the rest of the cornea. The epithelium is filled with thousands of tiny nerve endings that make the cornea extremely sensitive to pain when rubbed or scratched. The part of the epithelium that serves as the foundation on which the epithelial cells anchor and organize themselves is called the basement membrane.

Bowman's Layer

Lying directly below the basement membrane of the epithelium is a transparent sheet of tissue known as Bowman's layer. It is composed of strong layered protein fibers called collagen. Once injured, Bowman's layer can form a scar as it heals. If these scars are large and centrally located, some vision loss can occur.

Stroma

Beneath Bowman's layer is the stroma, which comprises about 90 percent of the cornea's thickness. It consists primarily of water (78 percent) and collagen (16 percent), and does not contain any blood vessels. Collagen gives the cornea its strength, elasticity, and form. The collagen's unique shape, arrangement, and spacing are essential in producing the cornea's light-conducting transparency.

Descemet's Membrane

Under the stroma is Descemet's membrane, a thin but strong sheet of tissue that serves as a protective barrier against infection and injuries. Descemet's membrane is composed of collagen fibers (different from those of the stroma) and is made by the endothelial cells that lie below it. Descemet's membrane is regenerated readily after injury.

Endothelium

The endothelium is the extremely thin, innermost layer of the cornea. Endothelial cells are essential in keeping the cornea clear. Normally, fluid leaks slowly from inside the eye into the middle corneal layer (stroma). The endothelium's primary task is to pump this excess fluid out of the stroma. Without this pumping action, the stroma would swell with water, become hazy, and ultimately opaque. In a healthy eye, a perfect balance is maintained between the fluid moving into the cornea and fluid being pumped out of the cornea. Once endothelium cells are destroyed by disease or trauma, they are lost forever. If too many endothelial cells are destroyed, corneal edema and blindness ensue, with corneal transplantation the only available therapy.

What is the function of the cornea?

Because the cornea is as smooth and clear as glass but is strong and durable, it helps the eye in two ways:

1. It helps to shield the rest of the eye from germs, dust, and other harmful matter. The cornea shares this protective task with the eyelids, the eye socket, tears, and the sclera, or white part of the eye.
2. The cornea acts as the eye's outermost lens. It functions like a window that controls and focuses the entry of light into the eye. The cornea contributes between 65-75 percent of the eye's total focusing power.

When light strikes the cornea, it bends - or refracts - the incoming light onto the lens. The lens further refocuses that light onto the retina, a layer of light sensing cells lining the back of the eye that starts the translation of light into vision. For you to see clearly, light rays must be focused by the cornea and lens to fall precisely on the retina. The retina converts the light rays into impulses that are sent through the optic nerve to the brain, which interprets them as images.

The refractive process is similar to the way a camera takes a picture. The cornea and lens in the eye act as the camera lens. The retina is similar to the film. If the image is not focused properly, the film (or retina) receives a blurry image.

The cornea also serves as a filter, screening out some of the most damaging ultraviolet (UV) wavelengths in sunlight. Without this protection, the lens and the retina would be highly susceptible to injury from UV radiation.

Refractive Errors

About 120 million people in the United States wear eyeglasses or contact lenses to correct nearsightedness, farsightedness, or astigmatism. These vision disorders - called refractive errors - affect the cornea and are the most common of all vision problems in this country.

Refractive errors occur when the curve of the cornea is irregularly shaped (too steep or too flat). When the cornea is of normal shape and curvature, it bends, or refracts, light on the retina with precision. However, when the curve of the cornea is irregularly shaped, the cornea bends light imperfectly on the retina. This affects good vision. The refractive process is similar to the way a camera takes a picture. The cornea and lens in your eye act as the camera lens. The retina is similar to the film. If the image is not focused properly, the film (or retina) receives a blurry image. The image that your retina "sees" then goes to your brain, which tells you what the image is.

When the cornea is curved too much, or if the eye is too long, faraway objects will appear blurry because they are focused in front of the retina. This is called myopia, or nearsightedness. Myopia affects over 25 percent of all adult Americans.

Hyperopia, or farsightedness, is the opposite of myopia. Distant objects are clear, and close-up objects appear blurry. With hyperopia, images focus on a point beyond the retina. Hyperopia results from an eye that is too short.

Astigmatism is a condition in which the uneven curvature of the cornea blurs and distorts both distant and near objects. A normal cornea is round, with even curves from side to side and top to bottom. With astigmatism, the cornea is shaped more like the back of a spoon, curved more in one direction than in another. This causes light rays to have more than one focal point and focus on two separate areas of the retina, distorting the visual image. Two-thirds of Americans with myopia also have astigmatism.

Refractive errors are usually corrected by eyeglasses or contact lenses. Although these are safe and effective methods for treating refractive errors, refractive surgeries are becoming an increasingly popular option.

How does the cornea respond to injury?

The cornea copes very well with minor injuries or abrasions. If the highly sensitive cornea is scratched, healthy cells slide over quickly and patch the injury before infection occurs and vision is affected. If the scratch penetrates the cornea more deeply, however, the healing process will take longer, at times resulting in greater pain, blurred vision, tearing, redness, and extreme sensitivity to light. These symptoms require professional treatment. Deeper scratches can also cause corneal scarring, resulting in a haze on the cornea that can greatly impair vision. In this case, a corneal transplant may be needed.

What are some diseases and disorders affecting the cornea?

Some diseases and disorders of the cornea are:

- **Allergies.** Allergies affecting the eye are fairly common. The most common allergies are those related to pollen, particularly when the weather is warm and dry. Symptoms can include redness, itching, tearing, burning, stinging, and watery discharge, although they are not usually severe enough to require medical attention. Antihistamine decongestant eyedrops can effectively reduce these symptoms, as does rain and cooler weather, which decreases the amount of pollen in the air.

An increasing number of eye allergy cases are related to medications and contact lens wear. Also, animal hair and certain cosmetics, such as mascara, face creams, and eyebrow pencil, can cause allergies that affect the eye. Touching or rubbing eyes after handling nail polish, soaps, or chemicals may cause an allergic reaction. Some people have sensitivity to lip gloss and eye makeup. Allergy symptoms are temporary and can be eliminated by not having contact with the offending cosmetic or detergent.

- **Conjunctivitis (Pink Eye).** This term describes a group of diseases that cause swelling, itching, burning, and redness of the conjunctiva, the protective membrane that lines the eyelids and covers exposed areas of the sclera, or white of the eye. Conjunctivitis can spread from one person to another and affects millions of Americans at any given time. Conjunctivitis can be caused by a bacterial or viral infection, allergy, environmental irritants, a contact lens product, eyedrops, or eye ointments.

At its onset, conjunctivitis is usually painless and does not adversely affect vision. The infection will clear in most cases without requiring medical care. But for some forms of conjunctivitis, treatment will be needed. If treatment is delayed, the infection may worsen and cause corneal inflammation and a loss of vision.

- **Corneal Infections.** Sometimes the cornea is damaged after a foreign object has penetrated the tissue, such as from a poke in the eye. At other times, bacteria or fungi from a contaminated contact lens can pass into the cornea. Situations like these can cause painful inflammation and corneal infections called keratitis. These infections can reduce visual clarity, produce corneal discharges, and perhaps erode the cornea. Corneal infections can also lead to corneal scarring, which can impair vision and may require a corneal transplant.

As a general rule, the deeper the corneal infection, the more severe the symptoms and complications. It should be noted that corneal infections, although relatively infrequent, are the most serious complication of contact lens wear.

Minor corneal infections are commonly treated with anti-bacterial eye drops. If the problem is severe, it may require more intensive antibiotic or anti-fungal treatment to eliminate the infection, as well as steroid eye drops to reduce inflammation. Frequent visits to an eye care professional may be necessary for several months to eliminate the problem.

- **Dry Eye.** The continuous production and drainage of tears is important to the eye's health. Tears keep the eye moist, help wounds heal, and protect against eye infection. In people with dry eye, the eye produces fewer or less quality tears and is unable to keep its surface lubricated and comfortable.

The tear film consists of three layers - an outer, oily (lipid) layer that keeps tears from evaporating too quickly and helps tears remain on the eye; a middle (aqueous) layer that nourishes the cornea and conjunctiva; and a bottom (mucin) layer that helps to spread the aqueous layer across the eye to ensure that the eye remains wet. As we age, the eyes usually produce fewer tears. Also, in some cases, the lipid and mucin layers produced by the eye are of such poor quality that tears cannot remain in the eye long enough to keep the eye sufficiently lubricated.

The main symptom of dry eye is usually a scratchy or sandy feeling as if something is in the eye. Other symptoms may include stinging or burning of the eye; episodes of excess tearing that follow periods of very dry sensation; a stringy discharge from the eye; and pain and redness of the eye. Sometimes people with dry eye experience heaviness of the eyelids or blurred, changing, or decreased vision, although loss of vision is uncommon.

Dry eye is more common in women, especially after menopause. Surprisingly, some people with dry eye may have tears that run down their cheeks. This is because the eye may be producing less of the lipid and mucin layers of the tear film, which help keep tears in the eye. When this happens, tears do not stay in the eye long enough to thoroughly moisten it.

Dry eye can occur in climates with dry air, as well as with the use of some drugs, including antihistamines, nasal decongestants, tranquilizers, and anti-depressant drugs. People with dry eye should let their health care providers know all the medications they are taking, since some of them may intensify dry eye symptoms.

People with connective tissue diseases, such as rheumatoid arthritis, can also develop dry eye. It is important to note that dry eye is sometimes a symptom of Sjögren's syndrome, a disease that attacks the body's lubricating glands, such as the tear and salivary glands. A complete physical examination may diagnose any underlying diseases.

Artificial tears, which lubricate the eye, are the principal treatment for dry eye. They are available over-the-counter as eye drops. Sterile ointments are sometimes used at night to help prevent the eye from drying. Using humidifiers, wearing wrap-around glasses when outside, and avoiding outside windy and dry conditions may bring relief. For people with severe cases of dry eye, temporary or permanent closure of the tear drain (small openings at the inner corner of the eyelids where tears drain from the eye) may be helpful.

- **Fuchs' Dystrophy.** Fuchs' dystrophy is a slowly progressing disease that usually affects both eyes and is slightly more common in women than in men. Although doctors can often see early signs of Fuchs' dystrophy in people in their 30s and 40s, the disease rarely affects vision until people reach their 50s and 60s.

Fuchs' dystrophy occurs when endothelial cells gradually deteriorate without any apparent reason. As more endothelial cells are lost over the years, the endothelium becomes less efficient at pumping water out of the stroma. This causes the cornea to swell and distort vision. Eventually, the epithelium also takes on water, resulting in pain and severe visual impairment.

Epithelial swelling damages vision by changing the cornea's normal curvature, and causing a sight-impairing haze to appear in the tissue. Epithelial swelling will also produce tiny blisters on the corneal surface. When these blisters burst, they are extremely painful.

At first, a person with Fuchs' dystrophy will awaken with blurred vision that will gradually clear during the day. This occurs because the cornea is normally thicker in the morning; it retains fluids

during sleep that evaporate in the tear film while we are awake. As the disease worsens, this swelling will remain constant and reduce vision throughout the day.

When treating the disease, doctors will try first to reduce the swelling with drops, ointments, or soft contact lenses. They also may instruct a person to use a hair dryer, held at arm's length or directed across the face, to dry out the epithelial blisters. This can be done two or three times a day.

When the disease interferes with daily activities, a person may need to consider having a corneal transplant to restore sight. The short-term success rate of corneal transplantation is quite good for people with Fuchs' dystrophy. However, some studies suggest that the long-term survival of the new cornea can be a problem.

Corneal Dystrophies

A corneal dystrophy is a condition in which one or more parts of the cornea lose their normal clarity due to a buildup of cloudy material. There are over 20 corneal dystrophies that affect all parts of the cornea. These diseases share many traits:

1. They are usually inherited.
2. They affect the right and left eyes equally.
3. They are not caused by outside factors, such as injury or diet.
4. Most progress gradually.
5. Most usually begin in one of the five corneal layers and may later spread to nearby layers.
6. Most do not affect other parts of the body, nor are they related to diseases affecting other parts of the eye or body.
7. Most can occur in otherwise totally healthy people, male or female.

Corneal dystrophies affect vision in widely differing ways. Some cause severe visual impairment, while a few cause no vision problems and are discovered during a routine eye examination. Other dystrophies may cause repeated episodes of pain without leading to permanent loss of vision.

Some of the most common corneal dystrophies include Fuchs' dystrophy, keratoconus, lattice dystrophy, and map-dot-fingerprint dystrophy.

- **Herpes Zoster (Shingles).** This infection is produced by the varicella-zoster virus, the same virus that causes chickenpox. After an initial outbreak of chickenpox (often during childhood), the virus remains inactive within the nerve cells of the central nervous system. But in some people, the varicella-zoster virus will reactivate at another time in their lives. When this occurs, the virus travels down long nerve fibers and infects some part of the body, producing a blistering rash (shingles), fever, painful inflammations of the affected nerve fibers, and a general feeling of sluggishness.

Varicella-zoster virus may travel to the head and neck, perhaps involving an eye, part of the nose, cheek, and forehead. In about 40 percent of those with shingles in these areas, the virus infects the cornea. Doctors will often prescribe oral anti-viral treatment to reduce the risk of the virus infecting cells deep within the tissue, which could inflame and scar the cornea. The disease may also cause decreased corneal sensitivity, meaning that foreign matter, such as eyelashes, in the eye are not felt as keenly. For many, this decreased sensitivity will be permanent.

Although shingles can occur in anyone exposed to the varicella-zoster virus, research has established two general risk factors for the disease: (1) Advanced age; and (2) A weakened immune system. Studies show that people over age 80 have a five times greater chance of having shingles

than adults between the ages of 20 and 40. Unlike herpes simplex I, the varicella-zoster virus does not usually flare up more than once in adults with normally functioning immune systems.

Be aware that corneal problems may arise months after the shingles are gone. For this reason, it is important that people who have had facial shingles schedule follow-up eye examinations.

- **Iridocorneal Endothelial Syndrome.** More common in women and usually diagnosed between ages 30-50, iridocorneal endothelial (ICE) syndrome has three main features: (1) Visible changes in the iris, the colored part of the eye that regulates the amount of light entering the eye; (2) Swelling of the cornea; and (3) The development of glaucoma, a disease that can cause severe vision loss when normal fluid inside the eye cannot drain properly. ICE is usually present in only one eye.

ICE syndrome is actually a grouping of three closely linked conditions: iris nevus (or Cogan-Reese) syndrome; Chandler's syndrome; and essential (progressive) iris atrophy (hence the acronym ICE). The most common feature of this group of diseases is the movement of endothelial cells off the cornea onto the iris. This loss of cells from the cornea often leads to corneal swelling, distortion of the iris, and variable degrees of distortion of the pupil, the adjustable opening at the center of the iris that allows varying amounts of light to enter the eye. This cell movement also plugs the fluid outflow channels of the eye, causing glaucoma.

The cause of this disease is unknown. While we do not yet know how to keep ICE syndrome from progressing, the glaucoma associated with the disease can be treated with medication, and a corneal transplant can treat the corneal swelling.

- **Keratoconus.** This disorder - a progressive thinning of the cornea - is the most common corneal dystrophy in the U.S., affecting one in every 2000 Americans. It is more prevalent in teenagers and adults in their 20s. Keratoconus arises when the middle of the cornea thins and gradually bulges outward, forming a rounded cone shape. This abnormal curvature changes the cornea's refractive power, producing moderate to severe distortion (astigmatism) and blurriness (nearsightedness) of vision. Keratoconus may also cause swelling and a sight-impairing scarring of the tissue.

Studies indicate that keratoconus stems from one of several possible causes:

1. An inherited corneal abnormality. About seven percent of those with the condition have a family history of keratoconus.
2. An eye injury, i.e., excessive eye rubbing or wearing hard contact lenses for many years.
3. Certain eye diseases, such as retinitis pigmentosa, retinopathy of prematurity, and vernal keratoconjunctivitis.
4. Systemic diseases, such as Leber's congenital amaurosis, Ehlers-Danlos syndrome, Down syndrome, and osteogenesis imperfecta.

Keratoconus usually affects both eyes. At first, people can correct their vision with eyeglasses. But as the astigmatism worsens, they must rely on specially fitted contact lenses to reduce the distortion and provide better vision. Although finding a comfortable contact lens can be an extremely frustrating and difficult process, it is crucial because a poorly fitting lens could further damage the cornea and make wearing a contact lens intolerable.

In most cases, the cornea will stabilize after a few years without ever causing severe vision problems. But in about 10 to 20 percent of people with keratoconus, the cornea will eventually become too scarred or will not tolerate a contact lens. If either of these problems occur, a corneal transplant may be needed. This operation is successful in more than 90 percent of those with

advanced keratoconus. Several studies have also reported that 80 percent or more of these patients have 20/40 vision or better after the operation.

The National Eye Institute is conducting a natural history study - called the Collaborative Longitudinal Evaluation of Keratoconus (CLEK) Study - to identify factors that influence the severity and progression of keratoconus.

- **Lattice Dystrophy.** Lattice dystrophy gets its name from an accumulation of amyloid deposits, or abnormal protein fibers, throughout the middle and anterior stroma. During an eye examination, the doctor sees these deposits in the stroma as clear, comma-shaped overlapping dots and branching filaments, creating a lattice effect. Over time, the lattice lines will grow opaque and involve more of the stroma. They will also gradually converge, giving the cornea a cloudiness that may also reduce vision.

In some people, these abnormal protein fibers can accumulate under the cornea's outer layer - the epithelium. This can cause erosion of the epithelium. This condition is known as recurrent epithelial erosion. These erosions: (1) Alter the cornea's normal curvature, resulting in temporary vision problems; and (2) Expose the nerves that line the cornea, causing severe pain. Even the involuntary act of blinking can be painful.

To ease this pain, a doctor may prescribe eye drops and ointments to reduce the friction on the eroded cornea. In some cases, an eye patch may be used to immobilize the eyelids. With effective care, these erosions usually heal within three days, although occasional sensations of pain may occur for the next six-to-eight weeks.

By about age 40, some people with lattice dystrophy will have scarring under the epithelium, resulting in a haze on the cornea that can greatly obscure vision. In this case, a corneal transplant may be needed. Although people with lattice dystrophy have an excellent chance for a successful transplant, the disease may also arise in the donor cornea in as little as three years. In one study, about half of the transplant patients with lattice dystrophy had a recurrence of the disease from between two to 26 years after the operation. Of these, 15 percent required a second corneal transplant. Early lattice and recurrent lattice arising in the donor cornea responds well to treatment with the excimer laser.

Although lattice dystrophy can occur at any time in life, the condition usually arises in children between the ages of two and seven.

- **Map-Dot-Fingerprint Dystrophy.** This dystrophy occurs when the epithelium's basement membrane develops abnormally (The basement membrane serves as the foundation on which the epithelial cells, which absorb nutrients from tears, anchor and organize themselves). When the basement membrane develops abnormally, the epithelial cells cannot properly adhere to it. This, in turn, causes recurrent epithelial erosions, in which the epithelium's outermost layer rises slightly, exposing a small gap between the outermost layer and the rest of the cornea.

Epithelial erosions can be a chronic problem. They may alter the cornea's normal curvature, causing periodic blurred vision. They may also expose the nerve endings that line the tissue, resulting in moderate to severe pain lasting as long as several days. Generally, the pain will be worse on awakening in the morning. Other symptoms include sensitivity to light, excessive tearing, and foreign body sensation in the eye.

Map-dot-fingerprint dystrophy, which tends to occur in both eyes, usually affects adults between the ages of 40 and 70, although it can develop earlier in life. Also known as epithelial basement membrane dystrophy, map-dot-fingerprint dystrophy gets its name from the unusual appearance of the cornea during an eye examination. Most often, the affected epithelium will have a map-like appearance, i.e., large, slightly gray outlines that look like a continent on a map. There may also be clusters of opaque dots underneath or close to the map-like patches. Less frequently, the irregular

basement membrane will form concentric lines in the central cornea that resemble small fingerprints.

Typically, map-dot-fingerprint dystrophy will flare up occasionally for a few years and then go away on its own, with no lasting loss of vision. Most people never know that they have map-dot-fingerprint dystrophy, since they do not have any pain or vision loss. However, if treatment is needed, doctors will try to control the pain associated with the epithelial erosions. They may patch the eye to immobilize it, or prescribe lubricating eye drops and ointments. With treatment, these erosions usually heal within three days, although periodic flashes of pain may occur for several weeks thereafter. Other treatments include anterior corneal punctures to allow better adherence of cells; corneal scraping to remove eroded areas of the cornea and allow regeneration of healthy epithelial tissue; and use of the excimer laser to remove surface irregularities.

- **Ocular Herpes.** Herpes of the eye, or ocular herpes, is a recurrent viral infection that is caused by the herpes simplex virus and is the most common infectious cause of corneal blindness in the U.S. Previous studies show that once people develop ocular herpes, they have up to a 50 percent chance of having a recurrence. This second flare-up could come weeks or even years after the initial occurrence.

Ocular herpes can produce a painful sore on the eyelid or surface of the eye and cause inflammation of the cornea. Prompt treatment with anti-viral drugs helps to stop the herpes virus from multiplying and destroying epithelial cells. However, the infection may spread deeper into the cornea and develop into a more severe infection called stromal keratitis, which causes the body's immune system to attack and destroy stromal cells. Stromal keratitis is more difficult to treat than less severe ocular herpes infections. Recurrent episodes of stromal keratitis can cause scarring of the cornea, which can lead to loss of vision and possibly blindness.

Like other herpetic infections, herpes of the eye can be controlled. An estimated 400,000 Americans have had some form of ocular herpes. Each year, nearly 50,000 new and recurring cases are diagnosed in the United States, with the more serious stromal keratitis accounting for about 25 percent. In one large study, researchers found that recurrence rate of ocular herpes was 10 percent within one year, 23 percent within two years, and 63 percent within 20 years. Some factors believed to be associated with recurrence include fever, stress, sunlight, and eye injury.

The National Eye Institute supported the Herpetic Eye Disease Study (HEDS), a group of clinical trials that studied various treatments for severe ocular herpes.

- **Pterygium.** A pterygium is a pinkish, triangular-shaped tissue growth on the cornea. Some pterygia grow slowly throughout a person's life, while others stop growing after a certain point. A pterygium rarely grows so large that it begins to cover the pupil of the eye.

Pterygia are more common in sunny climates and in the 20-40 age group. Scientists do not know what causes pterygia to develop. However, since people who have pterygia usually have spent a significant time outdoors, many doctors believe ultraviolet (UV) light from the sun may be a factor. In areas where sunlight is strong, wearing protective eyeglasses, sunglasses, and/or hats with brims are suggested. While some studies report a higher prevalence of pterygia in men than in women, this may reflect different rates of exposure to UV light.

Because a pterygium is visible, many people want to have it removed for cosmetic reasons. It is usually not too noticeable unless it becomes red and swollen from dust or air pollutants. Surgery to remove a pterygium is not recommended unless it affects vision. If a pterygium is surgically removed, it may grow back, particularly if the patient is less than 40 years of age. Lubricants can reduce the redness and provide relief from the chronic irritation.

- **Stevens-Johnson Syndrome.** Stevens-Johnson Syndrome (SJS), also called erythema multiforme major, is a disorder of the skin that can also affect the eyes. SJS is characterized by painful, blistering lesions on the skin and the mucous membranes (the thin, moist tissues that line body cavities) of the mouth, throat, genital region, and eyelids. SJS can cause serious eye problems, such as severe conjunctivitis; iritis, an inflammation inside the eye; corneal blisters and erosions; and corneal holes. In some cases, the ocular complications from SJS can be disabling and lead to severe vision loss.

Scientists are not certain why SJS develops. The most commonly cited cause of SJS is an adverse allergic drug reaction. Almost any drug - but most particularly sulfa drugs - can cause SJS. The allergic reaction to the drug may not occur until 7-14 days after first using it. SJS can also be preceded by a viral infection, such as herpes or the mumps, and its accompanying fever, sore throat, and sluggishness. Treatment for the eye may include artificial tears, antibiotics, or corticosteroids. About one-third of all patients diagnosed with SJS have recurrences of the disease.

SJS occurs twice as often in men as women, and most cases appear in children and young adults under 30, although it can develop in people at any age.

What is a corneal transplant? Is it safe?

A corneal transplant involves replacing a diseased or scarred cornea with a new one. When the cornea becomes cloudy, light cannot penetrate the eye to reach the light-sensitive retina. Poor vision or blindness may result.

In corneal transplant surgery, the surgeon removes the central portion of the cloudy cornea and replaces it with a clear cornea, usually donated through an eye bank. A trephine, an instrument like a cookie cutter, is used to remove the cloudy cornea. The surgeon places the new cornea in the opening and sews it with a very fine thread. The thread stays in for months or even years until the eye heals properly (Removing the thread is quite simple and can easily be done in an ophthalmologist's office). Following surgery, eye drops to help promote healing will be needed for several months.

Corneal transplants are very common in the United States; about 40,000 are performed each year. The chances of success of this operation have risen dramatically because of technological advances, such as less irritating sutures, or threads, which are often finer than a human hair; and the surgical microscope. Corneal transplantation has restored sight to many, who a generation ago would have been blinded permanently by corneal injury, infection, or inherited corneal disease or degeneration.

What problems can develop from a corneal transplant?

Even with a fairly high success rate, some problems can develop, such as rejection of the new cornea. Warning signs for rejection are decreased vision, increased redness of the eye, increased pain, and increased sensitivity to light. If any of these last for more than six hours, you should immediately call your ophthalmologist. Rejection can be successfully treated if medication is administered at the first sign of symptoms.

A study supported by the National Eye Institute (NEI) suggests that matching the blood type, but not tissue type, of the recipient with that of the cornea donor may improve the success rate of corneal transplants in people at high risk for graft failure. Approximately 20 percent of corneal transplant patients - between 6000-8000 a year - reject their donor corneas. The NEI-supported study, called the Collaborative Corneal Transplantation Study found that high-risk patients may reduce the likelihood of corneal rejection if their blood types match those of the cornea donors. The study also concluded that intensive steroid treatment after transplant surgery improves the chances for a successful transplant.

Are there alternatives to a corneal transplant?

Phototherapeutic keratectomy (PTK) is one of the latest advances in eye care for the treatment of corneal dystrophies, corneal scars, and certain corneal infections. Only a short time ago, people with these disorders would most likely have needed a corneal transplant. By combining the precision of the excimer laser with the control of a computer, doctors can vaporize microscopically thin layers of diseased corneal tissue and etch away the surface irregularities associated with many corneal dystrophies and scars. Surrounding areas suffer relatively little trauma. New tissue can then grow over the now-smooth surface. Recovery from the procedure takes a matter of days, rather than months as with a transplant. The return of vision can occur rapidly, especially if the cause of the problem is confined to the top layer of the cornea. Studies have shown close to an 85 percent success rate in corneal repair using PTK for well-selected patients.

The Excimer Laser

One of the technologies developed to treat corneal disease is the excimer laser. This device emits pulses of ultraviolet light - a laser beam - to etch away surface irregularities of corneal tissue. Because of the laser's precision, damage to healthy, adjoining tissue is reduced or eliminated.

The PTK procedure is especially useful for people with inherited disorders, whose scars or other corneal opacities limit vision by blocking the way images form on the retina. PTK has been approved by the U.S. Food and Drug Administration.

Current Corneal Research - that is following more than 1200 patients with the disease. Scientists are looking for answers to how rapidly their keratoconus will progress, how bad their vision will become, and whether they will need corneal surgery to treat it. Results from the CLEK Study will enable eye care practitioners to better manage this complex disease.

The NEI also supported the Herpetic Eye Disease Study (HEDS), a group of clinical trials that studied various treatments for severe ocular herpes. HEDS researchers reported that oral acyclovir reduced by 41 percent the chance that ocular herpes, a recurrent disease, would return. The study clearly showed that acyclovir therapy can benefit people with all forms of ocular herpes. Current HEDS research is examining the role of psychological stress and other factors as triggers of ocular herpes recurrences.

Vision research funded by the National Eye Institute (NEI) is leading to progress in understanding and treating corneal disease.

For example, scientists are learning how transplanting corneal cells from a patient's healthy eye to the diseased eye can treat certain conditions that previously caused blindness. Vision researchers continue to investigate ways to enhance corneal healing and eliminate the corneal scarring that can threaten sight. Also, understanding how genes produce and maintain a healthy cornea will help in treating corneal disease.

Genetic studies in families afflicted with corneal dystrophies have yielded new insight into 13 different corneal dystrophies, including keratoconus. To identify factors that influence the severity and progression of keratoconus, the NEI is conducting a natural history study - called the Collaborative Longitudinal Evaluation of Keratoconus (CLEK) Study

About the National Eye Institute

The National Eye Institute (NEI) is one of the Federal government's National Institutes of Health. It was established by Congress in 1968 to discover safe and effective ways of preventing, diagnosing,

and treating eye diseases and disorders. The NEI is the major sponsor of vision research in the U.S. This research is conducted at about 250 medical centers, hospitals, and universities across the country. Other clinical trials are conducted by NEI researchers at the National Institutes of Health campus in Bethesda, Maryland.

For more information about the NEI or NEI-sponsored clinical trials, contact the:

National Eye Institute
Building. 31, Room 6A32
31 Center Drive, MSC 2510
Bethesda, MD 20892-2510
Telephone: (301) 496-5248
Website: <http://www.nei.nih.gov>
E-Mail: 2020@nei.nih.gov

Other Information Sources:

American Academy of Ophthalmology
P.O. Box 7424
San Francisco, CA 94120-7424
(415) 561-8500
<http://www.eyenet.org>

American Optometric Association
243 North Lindbergh Boulevard
St. Louis, MO 63141
(314) 991-4100
<http://www.aoanet.org>

Eye Bank Association of America
1001 Connecticut Avenue, NW
Suite 601
Washington, DC 20036-5504
(202) 775-4999
<http://www.restorestight.org>

Food and Drug Administration
Office of Consumer Affairs
5600 Fishers Lane (HFE-88)
Rockville, MD 20857
1-888-463-6332
(301) 827-4420
<http://www.fda.gov>

National Keratoconus Foundation
Davis Building, Room 5069
8700 Beverly Boulevard
Los Angeles, CA 90048-1869

(310) 855-6455
1-800-521-2524 (California only)
<http://csmc.edu/nkcf>